Check for updates

STATE OF THE ART

Standardized Clinical Terms and Definitions for Interstitial Lung Disease

A Consensus Statement from the Fleischner Society

Christopher J. Ryerson[1], Alexander Bankier[3], Mary Beth Beasley[4], Kevin Brown[5], Thomas Colby[7], Vincent Cottin[8], Sujal Desai[9], Jeffrey Galvin[11,12], Linda B. Haramati[14], Lida P. Hariri[15], Yoshikazu Inoue[16,17], Takeshi Johkoh[18], Ho Yun Lee[19,20], Ann Leung[21], David Lynch[6], Nestor Muller[2], Andrew Nicholson[22,23], Suhail Raoof[25], Marie-Pierre Revel[26], Martine Remy-Jardin[27], Luca Richeldi[28], Jay H. Ryu[29], Mark Schiebler[30], Lynette Sholl[31], Nicola Sverzellati[32,33], William Travis[34], Simon L. F. Walsh[24], Athol U. Wells[10], Charles S. White[13], and Kerri A. Johannson[35]

Abstract

Background: Despite advances in diagnosis and management, the interstitial lung disease (ILD) lexicon is plagued by ambiguous and inconsistent terminology that complicates communication and impedes knowledge generation. The objective of this Fleischner Society Consensus Statement was to produce standardized terminology for ILD multidisciplinary diagnoses and major phenotypes.

Methods: Interviews with 10 experts were used to identify ILD clinical diagnoses and major phenotypes. The preferred terms for each entity and potential alternatives were identified, alongside the rationale for the preferred term. Entities with more than one potential term were the subject of an online modified Delphi survey posed to the 29 committee members, aiming to achieve consensus. Committee members rated their agreement with the initially preferred term—5 (*strongly agree*), 4 (*agree*), 3 (*neutral/unsure*), 2 (*disagree*), and 1 (*strongly disagree*)—with the option to provide additional comments. Median score ⩾4 and interquartile range ⩽1 were considered consensus agreement. Terms not reaching agreement were discussed by video conference, followed by an additional survey that incorporated feedback.

Results: From the 60 initial terms, there were two root terms that required upfront consensus before survey initiation (ILD and interstitial pneumonia) and another eight terms that had no alternative suggested by the committee or in the literature. Agreement was met by 47/50 terms (94%) in Round 1 of the survey. The three terms (6%) that did not reach agreement met agreement in Round 2.

Conclusions: This document provides standardized recommended terms for ILD multidisciplinary diagnoses and major phenotypes that will facilitate communication among clinicians, researchers, patients, and other stakeholders.

Keywords: ILD; pulmonary fibrosis; terminology; diagnosis; classification

The diagnosis and classification of interstitial lung disease (ILD) has been significantly advanced by previous consensus statements from the American Thoracic Society (ATS) and the European Respiratory Society (ERS) (1, 2). Despite these advances, the ILD lexicon is plagued by ambiguous and inconsistent terminology that complicates communication and impedes knowledge generation. A glossary of terms for thoracic imaging has been produced by the Fleischner Society (3, 4); however, no similar document exists to support standardization of terminology specific to the clinical aspects of ILD.

The objective of this Fleischner Society Consensus Statement was to produce a standardized ILD terminology from a multidisciplinary group of experts that will facilitate communication among clinicians, researchers, patients, and other stakeholders. This document focuses on clinical terms used to describe ILD diagnoses and major ILD phenotypes seen in adults, including both fibrotic and nonfibrotic ILDs. This document is not intended to address ILD classification schema or major ILD patterns observed on chest imaging or histopathology such as usual interstitial pneumonia (UIP) or nonspecific interstitial pneumonia (NSIP). We also do not provide specific diagnostic criteria (e.g., whether a biopsy is required to establish a high-confidence diagnosis), and we avoid infections, many causes of bronchiolitis, some rare exposure-related diseases, and most neoplasms that

(Received in original form May 10, 2025; accepted in final form July 30, 2025)

Correspondence and requests for reprints should be addressed to Christopher J. Ryerson, M.D., Department of Medicine, University of British Columbia, St. Paul's Hospital, Ward 8B, 1081 Burrard Street, Vancouver, BC V6Z 1Y6, Canada. E-mail: chris.ryerson@hli.ubc.ca.

This article has a related editorial.

A data supplement for this article is available via the Supplements tab at the top of the online article.

Artificial Intelligence Disclaimer: No artificial intelligence tools were used in writing this manuscript.

Am J Respir Crit Care Med Vol 211, Iss 10, pp 1756–1774, Oct 2025
Copyright © 2025 by the American Thoracic Society
Originally Published in Press as DOI: 10.1164/rccm.202505-1142SO on August 4, 2025
Internet address: www.atsjournals.org

[1]Department of Medicine and Centre for Heart Lung Innovation and [2]Department of Radiology, University of British Columbia, Vancouver, British Columbia, Canada; [3]Department of Radiology, University of Massachusetts Memorial Health and University of Massachusetts Chan Medical School, Worcester, Massachusetts; [4]Department of Pathology, Molecular and Cell-Based Medicine, Icahn School of Medicine at Mount Sinai, New York, New York; [5]Department of Medicine and [6]Department of Radiology, National Jewish Health, Denver, Colorado; [7]Department of Laboratory Medicine and Pathology, Mayo Clinic Arizona, Scottsdale, Arizona; [8]National Reference Centre for Rare Pulmonary Diseases, Department of Respiratory Medicine, Louis Pradel Hospital, Lyon Civil Hospitals, Lyon, France; [9]Department of Radiology and [10]Department of Respiratory Medicine, Royal Brompton Hospital and Imperial College London, London, United Kingdom; [11]Department of Diagnostic Radiology and Nuclear Medicine, [12]Pulmonary Division, Department of Medicine, and [13]Department of Thoracic Radiology, School of Medicine, University of Maryland, Baltimore, Maryland; [14]Department of Radiology and Biomedical Imaging, Yale School of Medicine, New Haven, Connecticut; [15]Department of Pathology and Division of Pulmonary and Critical Care Medicine, Department of Medicine, Massachusetts General Hospital, Harvard Medical School, Boston, Massachusetts; [16]Clinical Research Center, NHO Kinki Chuo Chest Medical Center, Osaka, Japan; [17]Department of Internal Medicine, Osaka Anti-tuberculosis Association, Osaka Fukujuji Hospital, Osaka, Japan; [18]Department of Radiology, Kansai Rosai Hospital, Amagasaki, Japan; [19]Department of Radiology and Center for Imaging Science, Samsung Medical Center, School of Medicine, and [20]Department of Health Sciences and Technology, SAIHST, Sungkyunkwan University, Seoul, Republic of Korea; [21]Department of Radiology, School of Medicine, Stanford University, Stanford, California; [22]Department of Histopathology, Royal Brompton and Harefield Hospitals, Guy's and St Thomas' NHS Foundation Trust, and [23]Department of Respiratory Pathology and [24]Faculty of Medicine, National Heart and Lung Institute, Imperial College London, London, United Kingdom; [25]Pulmonary, Critical Care and Sleep Medicine, Lenox Hill Hospital, New York, New York; [26]Department of Radiology, Hôpital Cochin, Assistance Publique des Hôpitaux de Paris, Université de Paris Cité, Paris, France; [27]Department of Thoracic Imaging, University Hospital Center of Lille, Lille, France; [28]Unità Operativa Complessa di Pneumologia, Fondazione Policlinico Universitario A. Gemelli IRCCS, Università Cattolica del Sacro Cuore, Rome, Italy; [29]Division of Pulmonary and Critical Care Medicine, Mayo Clinic, Rochester, Minnesota; [30]Department of Radiology, School of Medicine and Public Health, University of Wisconsin, Madison, Wisconsin; [31]Department of Pathology, Brigham and Women's Hospital, Boston, Massachusetts; [32]Department of Medicine and Surgery, University of Parma, Parma, Italy; [33]Department of Radiological Sciences, University Hospital of Parma, Parma, Italy; [34]Department of Pathology, Memorial Sloan Kettering Cancer Center, New York, New York; and [35]Department of Medicine and Snyder Institute for Chronic Diseases, University of Calgary, Calgary, Alberta, Canada

ORCID IDs: 0000-0003-1049-393X (C.J.R.); 0009-0006-1113-7821 (A.B.); 0000-0003-2340-1897 (M.B.B.); 0009-0006-5662-0120 (T.C.); 0000-0002-5591-0955 (V.C.); 0000-0003-0365-7422 (L.B.H.); 0000-0002-6190-624X (L.P.H.); 0000-0003-3994-874X (Y.I.); 0000-0001-9960-5648 (H.Y.L.); 0000-0001-7807-2643 (A.L.); 0000-0002-0657-8175 (N.M.); 0000-0003-3257-102X (A.N.); 0000-0001-8213-7817 (M.-P.R.); 0009-0001-4011-6257 (M.R.-J.); 0000-0001-8594-1448 (L.R.); 0000-0002-9576-2272 (J.H.R.); 0000-0002-9120-5428 (M.S.); 0000-0002-9532-9735 (L.S.); 0000-0002-9789-7648 (C.S.W.); 0000-0003-1205-5511 (K.A.J.).

occasionally present similarly to ILD. Furthermore, we did not provide distinct terms for overlapping conditions (e.g., idiopathic pulmonary fibrosis [IPF] plus pleuroparenchymal fibroelastosis [PPFE]), and we did not delve into many subgroups of disease (e.g., we did not list every possible drug, every exposure, every connective tissue disease [CTD]). We subcategorize ILD terms according to multiple features, including their etiology, pathobiology, and primarily location of histologic abnormality, recognizing that there is substantial overlap for many diagnoses.

Methods

The study design is shown in Figure 1. A total of 60 ILD diagnoses and major phenotypes were identified on the basis of a series of one-on-one interviews with 10 committee members (conducted by C.J.R. and K.A.J.). These interviews were used to suggest an initial preferred term for each entity, as well as possible alternatives, and were then supplemented by input from the full committee and additional unstructured literature reviews. From the 60 terms, two root terms required upfront consensus before survey initiation (ILD and interstitial pneumonia) and another eight terms that had no alternative term suggested in the literature or by the committee. Statements supporting the preferred term over the alternatives for the remaining 50 terms were drafted and provided as an online modified Delphi survey, using Qualtrics, to all 29 committee members selected from within the membership of the Fleischner Society (range of clinical experience = 9–45 yr) (5), which included 9 ILD pulmonologists, 15 chest radiologists, and 5 lung pathologists. Committee members rated their agreement with the initially preferred term—as 5 (*strongly agree*), 4 (*agree*), 3 (*neutral/unsure*), 2 (*disagree*), or 1 (*strongly disagree*)—with the option to provide additional comments. Although there was a general desire to replace eponyms and biologically inaccurate terms, there were no specific instructions provided to committee members for voting purposes. Therefore, the recommended terms reflect the opinions and consensus of the committee given the absence of direct evidence suggesting the benefit of one term over another. A median score of 4 or higher and an interquartile range of 1 or less were considered consensus for agreement (6), which was met by 47/50 terms (94%) in the first round of the survey. The full committee then discussed, by video conference, the three terms (6%) that did not reach these thresholds: alveolar macrophage pneumonia (AMP), idiopathic diffuse alveolar damage (DAD), and radiotherapy-associated lung injury. A second round of the survey then reached agreement for all terms. The preferred terms and their nonpreferred alternatives are presented in Tables 1–9, with the rationale for each preferred term provided in the following text. (For the wording of each question and voting results, *see* the data supplement.) Significant changes from more common historical terms are summarized in Table 10.

Major Diagnoses and Phenotypes

ILD

ILD defines a group of pulmonary disorders typically involving the pulmonary parenchyma and, in some cases, the small airways. Although ILD can affect many lung compartments, the abnormalities are not usually predominated by disease in the large airways, pulmonary vasculature, or pleural space. Historically, the most used term for this group of disorders is "ILD," with

Contents

Methods
Major Diagnoses and Phenotypes
- ILD
- Interstitial Pneumonia
- Interstitial Lung Abnormality (ILA)
- Progressive Pulmonary Fibrosis (PPF)
- Acute exacerbation of ILD (AE-ILD)
- Diffuse Alveolar Hemorrhage (DAH)
- Combined Pulmonary Fibrosis and Emphysema (CPFE)
- Familial ILD

Interstitial Pneumonias
- IPF
- Idiopathic NSIP
- Idiopathic Bronchiolocentric Interstitial Pneumonia (iBIP)
- Idiopathic Pleuroparenchymal Fibroelastosis
- Idiopathic DAD
- Idiopathic Lymphoid Interstitial Pneumonia (LIP)
- Unclassifiable ILD

Alveolar Filling Disorders
- Cryptogenic OP
- Acute Eosinophilic Pneumonia (AEP)
- Chronic Eosinophilic Pneumonia (CEP)
- Lipoid Pneumonia
- AMP
- Respiratory Bronchiolitis ILD (RB-ILD)
- Pulmonary Alveolar Proteinosis (PAP)

Immune Disorder-related ILDs
- CTD-associated ILD/Systemic Autoimmune Rheumatic Disease (SARD)-associated ILD
- Interstitial Pneumonia with Autoimmune Features (IPAF)
- Granulomatosis with Polyangiitis (GPA)
- Microscopic Polyangiitis (MPA)
- Eosinophilic Granulomatosis with Polyangiitis (EGPA)
- Anti-Glomerular Basement Membrane (Anti-GBM) Disease
- Inflammatory Bowel Disease-associated ILD (IBD-ILD)
- Granulomatous-Lymphocytic ILD (GL-ILD)
- IgG4-related ILD

Exposure-related/Secondary
- HP
- Hot Tub Lung
- Flock Worker's Lung
- Silicosis
- Asbestosis
- Coal Pneumoconiosis
- Berylliosis
- Hard Metal Pneumoconiosis
- Drug-associated ILD
- Radiotherapy-associated Lung Injury
- Post-ARDS Lung Injury
- Post–Infectious Lung Injury

Neoplasms Presenting as ILD
- Pulmonary Langerhans Cell Histiocytosis (PLCH)
- Erdheim–Chester Disease
- Lymphangioleiomyomatosis (LAM)

ILDs Induced by Lymphoproliferative Disease
- Pulmonary Amyloidosis
- Light Chain Deposition Disease (LCCD)
- Pulmonary Lymphomatoid Granulomatosis
- Castleman Disease-associated ILD

Congenital/Genetic
- Folliculin Deficiency-associated ILD
- Neurofibromatosis-associated ILD
- Acid Sphingomyelinase Deficiency (ASMD)-associated ILD
- α-Galactosidase A Deficiency-associated ILD
- Glucocerebrosidase Deficiency–associated ILD
- Congenital Pulmonary Lymphangiectasis
- Diffuse Pulmonary Lymphangiomatosis

Other
- Sarcoidosis
- Pulmonary Alveolar Microlithiasis
- Idiopathic Diffuse Pulmonary Ossification (DPO)

Conclusions

alternatives including "diffuse parenchymal lung disease," "diffuse multicompartment lung injury," "infiltrative lung disease," "fibrosing lung disease," and "diffuse infiltrative lung disease." Although diffuse parenchymal lung disease has been suggested as the most accurate of these terms, it is also imprecise, as many of these diseases affect different lung compartments. Despite the absence of a major advantage, the historically established term of "ILD" remains preferred.

Interstitial Pneumonia

There is need for a term that captures the entities that were described in the 2013 ATS/ERS statement on the classification of the idiopathic interstitial pneumonias (2). Collectively, these are a group of diseases that are either interstitial or alveolar filling disorders, with some affecting both compartments. The most used term historically is "idiopathic interstitial pneumonia"; however, an increasing number of studies suggest that it is no longer appropriate to consider many of these entities to be idiopathic, and some have advocated that the "idiopathic" component of this term be removed. Substituting "pneumon*itis*" (e.g., "interstitial pneumonitis") has also been suggested but implies a significant amount of inflammation that is not present for some entities within this category. Although "pneumonia" is often used to describe infectious etiologies on lung pathology (4), this has also been used to describe some alveolar filling disorders included within these noninfectious diagnoses. "Interstitial pneumonia" is, therefore, the most appropriate term to refer to these entities.

Interstitial Lung Abnormality (ILA)

ILA refers to interstitial findings identified on computed tomography that are associated with a risk of progression to ILD but that are currently below the threshold of definite clinical significance, thus distinguishing "abnormality" from "disease." "ILA" is the preferred term in the literature and was previously endorsed and defined in previous Fleischner Society publications (4, 7). Alternative terms, including "subclinical ILD," "pre-clinical ILD," and "incidental ILD" have limited use in the literature and offer no clear advantage.

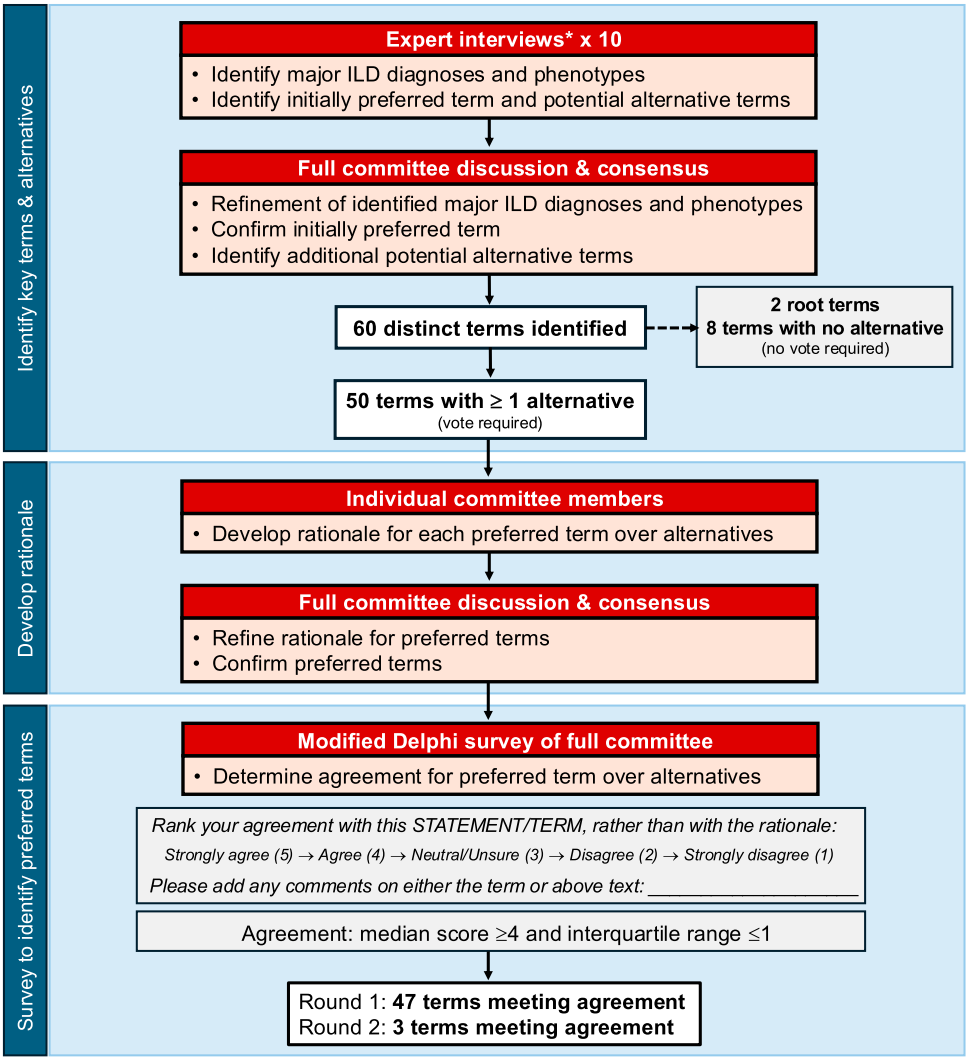

Figure 1. Study design. *Interviewees included J.G., A.U.W., K.B., M.S., M.B.B., V.C., L.H., A.N., N.M., and J.H.R. ILD = interstitial lung disease.

Progressive Pulmonary Fibrosis (PPF)

PPF describes a group of patients with fibrotic lung disease who meet guideline-defined criteria for progression in at least two domains (clinical, physiologic, or radiologic), usually excluding IPF (8). "PPF" was also referred to as "progressive fibrosing ILD" in initial pharmaceutical trials and as a "progressive fibrotic phenotype" (9). Clinical practice guidelines have suggested "PPF" as the preferred term (8), justifying this on the basis of the term's simplicity, the frequent impact beyond the interstitial space, the absence of a specific and unique genotype that would support the use of "phenotype," and the consistent phraseology with IPF that has a similar clinical course. Although use of "ILD" as a root term would improve terminological consistency with many ILDs (e.g., "progressive fibrosing ILD"), the term "PPF" was considered appropriate, as this entity is a novel supracategorization of several variably named disorders that are all characterized by fibrosis.

Acute exacerbation of ILD (AE-ILD)

AE-IPF is defined as an acute, clinically significant respiratory deterioration characterized by new widespread alveolar abnormality in a patient with underlying IPF (10), with similar events also occurring in other ILD subtypes. Given the preference to use ILD as the preferred root term, "acute exacerbation of ILD" is the preferred term over the alternatives of "acute exacerbation of pulmonary fibrosis" and "acute exacerbation of interstitial pneumonia." Patients with a specific ILD diagnosis should be labeled according to that diagnosis (e.g., "AE-IPF").

Diffuse Alveolar Hemorrhage (DAH)

DAH refers to diffuse bleeding in the lung that originates within the microvasculature within the alveoli walls. DAH is a nonspecific injury pattern for which a specific cause should be sought (e.g., vasculitis, drug reaction), although some cases remain idiopathic. "DAH" is the preferred term for this entity because it highlights both the diffuse extent and the alveolus as the primary site of injury. The alternative terms of "diffuse pulmonary hemorrhage," "alveolar hemorrhage," and "alveolar hemorrhage syndrome" are not as descriptively accurate or precise.

Table 1. Preferred Terms and Abbreviations for Major Categories and Phenotypes

Preferred Term	Preferred Abbreviations	Nonpreferred Alternatives
Interstitial lung disease	ILD	• Diffuse parenchymal lung disease • Diffuse multicompartment lung injury • Infiltrative lung disease • Fibrosing lung disease • Diffuse infiltrative lung disease
Interstitial pneumonia	IP	• Idiopathic interstitial pneumonia • Interstitial pneumonitis • Idiopathic interstitial pneumonitis
Interstitial lung abnormality	ILA	• Subclinical ILD • Preclinical ILD • Incidental ILD
Progressive pulmonary fibrosis	PPF	• Progressive fibrosing interstitial lung disease • Progressive fibrotic phenotype
Acute exacerbation of interstitial lung disease Diffuse alveolar hemorrhage	AE-ILD DAH	• Acute exacerbation of pulmonary fibrosis • Diffuse pulmonary hemorrhage • Alveolar hemorrhage • Alveolar hemorrhage syndrome
Combined pulmonary fibrosis and emphysema	CPFE	N/A
Familial interstitial lung disease	Familial ILD	• Familial pulmonary fibrosis • Familial interstitial pneumonia • Familial interstitial lung abnormality

Definition of abbreviation: N/A = not applicable.

Table 2. Preferred Terms and Abbreviations for Interstitial Pneumonias

Preferred Term	Preferred Abbreviations	Nonpreferred Alternatives
Idiopathic pulmonary fibrosis	IPF	• Cryptogenic fibrosing alveolitis • Idiopathic UIP • Primary UIP
Idiopathic nonspecific interstitial pneumonia	iNSIP	• Nonspecific interstitial pneumonia
Idiopathic bronchiolocentric interstitial pneumonia	iBIP	• Cryptogenic hypersensitivity pneumonitis • Antigen-indeterminate hypersensitivity pneumonitis • Airway-centric/centered disease • Airway-centric/centered fibrosis • Airway-centered interstitial pneumonia • Airway-centered interstitial fibrosis • Bronchiolocentric pattern of IP • Bronchiolocentric pattern of interstitial fibrosis
Idiopathic pleuroparenchymal fibroelastosis	iPPFE	• Pulmonary upper lobe fibrosis
Idiopathic diffuse alveolar damage	Idiopathic DAD	• Acute interstitial pneumonia • Acute interstitial pneumonitis • Hamman-Rich syndrome • Idiopathic acute respiratory distress syndrome
Idiopathic lymphoid interstitial pneumonia	iLIP	• Idiopathic lymphocytic interstitial pneumonia
Unclassifiable ILD	Unclassifiable ILD	• Unclassified interstitial lung disease • Unclassifiable pulmonary fibrosis • Unclassifiable fibrosing lung disease

Definition of abbreviation: UIP = usual interstitial pneumonia.

Table 3. Preferred Terms and Abbreviations for Alveolar Filling Disorders

Preferred Term	Preferred Abbreviations	Nonpreferred Alternatives
Cryptogenic organizing pneumonia	COP	• Idiopathic organizing pneumonia • Bronchiolitis obliterans organizing pneumonia
Acute eosinophilic pneumonia	AEP	N/A
Chronic eosinophilic pneumonia	CEP	N/A
Lipoid pneumonia	N/A	• Exogenous/endogenous lipoid pneumonia • Lipoid pneumonitis • Cholesterol pneumonia
Alveolar macrophage pneumonia	AMP	• Desquamative interstitial pneumonia • Idiopathic desquamative interstitial pneumonia • Alveolar macrophage filling disorder • Smoking-related interstitial fibrosis • Smoking-related interstitial lung disease
Respiratory bronchiolitis interstitial lung disease	RB-ILD	• Idiopathic respiratory bronchiolitis ILD
Pulmonary alveolar proteinosis	PAP	• Alveolar proteinosis

Definition of abbreviation: N/A = not applicable.

Combined Pulmonary Fibrosis and Emphysema (CPFE)

CPFE describes the concurrent presence of both fibrosis and emphysema, although thresholds and subtypes for each component vary across previous publications (11). A recent multisociety research statement proposed that CPFE be defined by the presence of emphysema affecting more than 5% of total lung volume plus any amount of any subtype of lung fibrosis, with additional clinical and physiological criteria also suggested for situations when greater clinical relevance is desired, although more data are needed to support these thresholds and potential morphologic subgroups (12). The term "CPFE" has consistently been used to describe this entity without a viable alternative suggested; however, distinct morphologic subtypes of fibrosis and emphysema should be defined when using this term.

Table 4. Preferred Terms and Abbreviations for Immune Disorder-related Interstitial Lung Diseases

Preferred Term	Preferred Abbreviations	Nonpreferred Alternatives
Connective tissue disease–associated interstitial lung disease*	CTD-ILD*	• Collagen vascular disease–associated interstitial lung disease • Autoimmune interstitial lung disease
Interstitial pneumonia with autoimmune features	IPAF	• Interstitial lung disease with autoimmune features
Granulomatosis with polyangiitis	GPA	• Wegener's granulomatosis
Microscopic polyangiitis	MPA	N/A
Eosinophilic granulomatosis with polyangiitis	EGPA	• Churg-Strauss syndrome • Allergic angiitis and granulomatosis • Allergic granulomatosis
Anti–glomerular basement membrane disease	Anti-GBM disease	• Anti-GBM antibody disease • Goodpasture's syndrome • Goodpasture's disease
Inflammatory bowel disease–associated interstitial lung disease	IBD-ILD	• Inflammatory bowel disease–associated lung disease
Granulomatous-lymphocytic interstitial lung disease	GL-ILD	• Common variable immunodeficiency–associated interstitial lung disease • Granulomatous-lymphocytic lung disease
IGG4-related interstitial lung disease	IGG4-ILD	• IgG4-related lung disease • Hyper–IgG4-related lung disease

Definition of abbreviation: N/A = not applicable.
*Systemic autoimmune rheumatic disease–associated interstitial lung disease is also considered appropriate on the basis of a recommendation from a recent guideline from the American College of Rheumatology and the American College of Chest Physicians.

Table 5. Preferred Terms and Abbreviations for Secondary and Exposure-related Interstitial Lung Diseases

Preferred Term	Preferred Abbreviations	Nonpreferred Alternatives
Hypersensitivity pneumonitis	HP	• Hypersensitivity pneumonia • Extrinsic allergic alveolitis
Hot tub lung	N/A	• Hot tub lung disease • Hot tub pneumonitis • Hot tub–associated hypersensitivity pneumonitis
Flock worker's lung	N/A	• Flock lung • Nylon flock–associated interstitial lung disease • Flock worker's pneumoconiosis
Silicosis	N/A	• Pneumoconiosis due to silica • Silica pneumoconiosis • Silicopneumoconiosis
Asbestosis	N/A	• Pneumoconiosis due to asbestos • Asbestos-related interstitial lung disease
Coal pneumoconiosis	N/A	• Coal worker's pneumoconiosis • Pneumoconiosis due to coal • Mixed dust pneumoconiosis
Berylliosis	N/A	• Chronic beryllium disease • Acute/chronic berylliosis • Pneumoconiosis due to beryllium • Beryllium pneumoconiosis
Hard metal pneumoconiosis	N/A	• "x" pneumoconiosis (cobalt, tungsten, nickel, titanium) • Giant cell interstitial pneumonia • Hard metal–associated interstitial lung disease • Hard metal–associated lung injury • Pneumoconiosis due to "x" hard metal
Drug-associated interstitial lung disease	Drug-associated ILD	• Drug-induced lung disease • Medication-associated interstitial lung disease • Drug-associated lung injury • Medication-associated lung injury • Drug-related pneumonitis
Radiotherapy-associated lung injury	N/A	• Radiotherapy-induced interstitial lung disease • Radiotherapy-associated interstitial lung disease • Radiotherapy-induced lung injury • Radiation-associated lung injury • Radiation-induced lung injury
Post–acute respiratory disease syndrome lung injury	Post-ARDS lung injury	• Post-ARDS interstitial lung disease
Post–infectious lung injury	N/A	• Post–infectious interstitial lung disease

Definition of abbreviation: N/A = not applicable.

Table 6. Preferred Terms and Abbreviations for Neoplasms Presenting as Interstitial Lung Diseases

Preferred Term	Preferred Abbreviations	Nonpreferred Alternatives
Pulmonary Langerhans cell histiocytosis	PLCH	• Pulmonary/systemic histiocytosis • Histiocytosis X • Eosinophilic granuloma
Erdheim–Chester disease	N/A	• Polyostotic sclerosing histiocytosis • Non–Langerhans histiocytosis
Lymphangioleiomyomatosis	LAM	N/A

Definition of abbreviation: N/A = not applicable.

Table 7. Preferred Terms and Abbreviations for Lymphoproliferative Disorder–related Interstitial Lung Diseases

Preferred Term	Preferred Abbreviations	Nonpreferred Alternatives
Light chain deposition disease	LCDD	• Non–amyloid light chain deposition disease
Pulmonary amyloidosis	N/A	N/A
Pulmonary lymphomatoid granulomatosis	N/A	N/A
Castleman disease–associated interstitial lung disease	Castleman disease–associated ILD	• Multicentric Castleman disease

Definition of abbreviation: N/A = not applicable.

Familial ILD

Familial ILD describes the presence of ILD in an individual with at least one first-degree biological relative who is also affected by an ILD, inferring increased likelihood of underlying genetic risk (13). The term "familial ILD" is preferred over "familial pulmonary fibrosis," given that the disease is not necessarily fibrotic, and also over "familial interstitial pneumonia," given the preference to use "ILD" as an overarching root term. "Familial ILA" is not preferred, as ILA is defined as an abnormality that lacks clear disease manifestations (7).

Interstitial Pneumonias

IPF

IPF is defined as a chronic fibrosing interstitial pneumonia of unknown cause associated with radiologic and histologic features of UIP (8). "Cryptogenic fibrosing alveolitis" was used historically to describe this entity, which is now most commonly referred to as "IPF." The term "idiopathic UIP" has also been advocated as a more precise representation of the radiological/histopathological findings, but with limited uptake in the literature. There have similarly been insufficient advances in the characterization of distinct biological and/or genetic subtypes of IPF (e.g., specific gene mutations) to suggest incorporation of these features into the name itself for specific subtypes. Despite the imprecise biological meaning and the ambiguity with other forms of pulmonary fibrosis that also lack a clear current understanding of their etiology (i.e., that could also currently be considered "idiopathic" forms of pulmonary fibrosis), the term "IPF" has remained most commonly used in the literature to refer to this group of patients and has been endorsed in several consensus statements and guidelines (2, 8, 14, 15).

Idiopathic NSIP

NSIP was first proposed in 1994 as a distinct histological pattern characterized by varying amounts of interstitial inflammation and fibrosis with a uniform appearance (2, 16). "Idiopathic NSIP" was given provisional status as a multidisciplinary diagnosis in 2002 and was formally recognized in the 2013 ATS/ERS statement on the classification of idiopathic interstitial pneumonias (1, 2). Many patients with a pattern of NSIP on histology are found to have "secondary" (e.g., drug or CTD-associated) rather than "idiopathic" NSIP after further review or during long-term follow-up (17). "Idiopathic NSIP" refers to the idiopathic presentation of the radiologic and/or pathologic pattern of NSIP, with no appropriate alternative term proposed for either the diagnosis or pattern.

Idiopathic Bronchiolocentric Interstitial Pneumonia (iBIP)

Many patients with interstitial pneumonia have a major component of airway-centered disease. This pattern is most frequently seen in the etiologic setting of hypersensitivity pneumonitis (HP) (where the imaging and

Table 8. Preferred Terms and Abbreviations for Congenital/Genetic Disorders Presenting as Interstitial Lung Disease

Preferred Term	Preferred Abbreviations	Nonpreferred Alternatives
Folliculin deficiency	N/A	• Birt-Hogg-Dubé syndrome
Neurofibromatosis-associated ILD	N/A	• Neurofibromatosis-associated lung disease
Acid sphingomyelinase deficiency–associated interstitial lung disease	ASMD-ILD	• Niemann-Pick–associated interstitial lung disease • Niemann-Pick–associated lung disease
α-Galactosidase A deficiency–associated interstitial lung disease	α-Galactosidase A deficiency–associated ILD	• Fabry disease • Angiokeratoma corporis diffusum
Glucocerebrosidase deficiency–associated interstitial lung disease	Glucocerebrosidase deficiency–associated ILD	• Gaucher disease
Congenital pulmonary lymphangiectasia	N/A	• Primary pulmonary lymphangiectasis
Diffuse pulmonary lymphangiomatosis	N/A	• Pulmonary lymphangiomatosis • Lymphangiomatosis

Definition of abbreviation: N/A = not applicable.

Table 9. Preferred Terms and Abbreviations for Miscellaneous Interstitial Lung Diseases

Preferred Term	Preferred Abbreviations	Nonpreferred Alternatives
Sarcoidosis	N/A	• Sarcoid
Pulmonary alveolar microlithiasis	N/A	• Alveolar microlithiasis
Idiopathic diffuse pulmonary ossification	Idiopathic DPO	N/A

Definition of abbreviation: N/A = not applicable.

Table 10. Significant Changes from Previously Used Terminology

Preferred Term	Previous Term(s)	Main Rationale
Interstitial pneumonia	• Idiopathic interstitial pneumonia	• Many subtypes included under the previous umbrella term of "idiopathic interstitial pneumonia" were not idiopathic • A more comprehensive approach that includes known and unknown etiologies is more clinically relevant
Progressive pulmonary fibrosis	• Progressive fibrosing ILD • Progressive fibrotic phenotype	• Consistent with clinical practice guideline recommendation
Idiopathic bronchiolocentric interstitial pneumonia	• Cryptogenic HP • Antigen-indeterminate HP • Airway-centric/centered disease • Airway-centric/centered fibrosis • Airway-centered interstitial pneumonia • Airway-centered interstitial fibrosis • Bronchiolocentric pattern of interstitial pneumonia	• Acknowledges the multiple possible causes of this imaging and biopsy pattern • Calls attention to the need for careful consideration of all potential causes of airway-centered interstitial pneumonia • Harmonizes the classification and terminology across major interstitial pneumonia patterns and multidisciplinary diagnoses • Facilitates future research to identify and better define potentially unique disease subtypes
Alveolar macrophage pneumonia	• Desquamative interstitial pneumonia • Idiopathic desquamative interstitial pneumonia • Alveolar macrophage filling disorder • Smoking-related interstitial fibrosis • Smoking-related interstitial lung disease	• More accurately represents the underlying pathobiology of disease
Radiotherapy-associated lung injury	• Radiotherapy-induced ILD • Radiotherapy-associated ILD • Radiotherapy-induced lung injury • Radiation-associated lung injury • Radiation-induced lung injury	• Better conveys the frequent diagnostic uncertainty (i.e., using "associated rather than "induced") • Reflects the low potential for ongoing "disease" progression in patients with more focal abnormality
Folliculin deficiency	• Birt-Hogg-Dubé syndrome	• More accurately represents the underlying pathobiology of disease
Acid sphingomyelinase deficiency–associated ILD	• Niemann-Pick–associated ILD • Niemann-Pick–associated lung disease	• More accurately represents the underlying pathobiology of disease • More appropriately excludes the distinct Niemann-Pick Type C
α-Galactosidase A deficiency–associated ILD	• Fabry disease • Angiokeratoma corporis diffusum	• More accurately represents the underlying pathobiology of disease • Better acknowledges the multisystem involvement (compared with angiokeratoma corporis diffusum)
Glucocerebrosidase deficiency–associated ILD	• Gaucher disease	• More accurately represents the underlying pathobiology of disease

Definition of abbreviations: HP = hypersensitivity pneumonitis; ILD = interstitial lung disease.

biopsy pattern has previously been described as "typical HP") (18, 19), as well as CTD-associated ILD (CTD-ILD), aspiration, and inhalational or medication exposures, with a substantial percentage of patients lacking an underlying etiology despite comprehensive evaluation (20, 21). Patients with an airway-centered pattern of disease with an unknown etiology despite a comprehensive evaluation for potential causes have had a variety of terms used to refer to the clinical diagnosis, including "cryptogenic HP," "antigen-indeterminate HP," "airway-centric/centered disease," "airway-centric/centered fibrosis," "airway-centered interstitial pneumonia," "airway-centered interstitial fibrosis," "bronchiolocentric pattern of interstitial pneumonia," "bronchiolocentric pattern of interstitial fibrosis," and others. When a specific etiology cannot be identified after a thorough evaluation, the preferred term of "iBIP" calls attention to the need for careful consideration of all potential causes of this pattern, harmonizes the classification and terminology across major interstitial pneumonia patterns and multidisciplinary diagnoses, and facilitates future research to identify and better define potentially unique disease subtypes. This is a new term, and it is uncertain at this time whether iBIP will replace the multiple previous terms that have been used to describe these patients.

Idiopathic Pleuroparenchymal Fibroelastosis

PPFE is a rare interstitial pneumonia characterized by a combination of fibrosis involving the visceral pleura and fibroelastotic changes predominating in the subpleural lung parenchyma of the upper lobes (2, 22). PPFE is rarely idiopathic, and the finding more often occurs in combination with a variety of other ILDs (e.g., IPF) and underlying precipitants (e.g., bone marrow transplant). "Pulmonary upper lobe fibrosis" was sporadically used in the literature; however, this term is no longer in common use, with general acceptance of "idiopathic PPFE" when an underlying etiology is not identified.

Idiopathic DAD

DAD is an acute process with nonspecific clinical and radiological findings of acute respiratory disease syndrome (ARDS) and the pathological features of (acute/organizing) lung damage that can occur with a variety of etiologies (23). "Acute interstitial pneumonia" was included in the 2013 ATS/ERS statement on the classification of idiopathic interstitial pneumonias to represent the idiopathic presentation of DAD (2); however, "acute interstitial pneumonia" is imprecise, given that other ILDs (e.g., organizing pneumonia [OP]) can also present acutely. "Idiopathic ARDS" is less favored because ARDS typically occurs secondary to a large variety of conditions and is rarely considered idiopathic itself. "Hamman-Rich syndrome" is an outdated eponym that has been replaced by more histologically accurate terms. Despite limited use in the literature, "idiopathic DAD" is histologically accurate and consistent with other terms that are in more common use (e.g., "idiopathic NSIP").

Idiopathic Lymphoid Interstitial Pneumonia (LIP)

LIP is a rare interstitial pneumonia characterized histopathologically by interstitial and alveolar space infiltration by lymphocytes, plasma cells, and other lymphoreticular elements. Chest imaging findings can include lower lung–predominant interstitial abnormalities, small nodules, and randomly distributed thin-walled cysts (24). The large majority of patients with a LIP pattern have an identifiable underlying cause, most commonly including CTD and immune deficiencies. "Lymphoid" is preferred over "lymphocytic," as the proliferation of cells arise from the *lymphoid* tissues within the lung, rather than referring to *lymphocytic* infiltration that suggests a specific proliferating cell type. Although some have reasonably advocated that the term "LIP" be abandoned given its lack of specificity (25), the use of "idiopathic LIP" is consistent with the terminology used in the 2013 ATS/ERS statement on the classification of idiopathic interstitial pneumonias (2).

Unclassifiable ILD

Unclassifiable ILD refers to the 10–20% of patients with ILD of uncertain etiology (26), defined as lacking a leading diagnosis that has more than 50% confidence after multidisciplinary review (27). The 2013 ATS/ERS statement used the term "unclassifiable idiopathic interstitial pneumonia" that was initially described in the 2002 statement (1, 2); however, using "idiopathic interstitial pneumonia" in this label inappropriately suggests that the differential diagnosis exclusively or at least primarily includes the entities previously considered within this more limited category of idiopathic interstitial pneumonia. "Unclassifiable interstitial pneumonia" may be an appropriate alternative but has not been used as frequently in the literature. The less common alternatives of "unclassified ILD," "unclassifiable pulmonary fibrosis," and "unclassifiable fibrosing lung disease" either offer a minor semantic change or inappropriately suggest the required presence of fibrosis. Unclassifiable ILD should not be considered a specific entity but, rather, a set of cases where a diagnosis cannot be reached.

Alveolar Filling Disorders

Cryptogenic OP

"Cryptogenic OP" (COP) describes the idiopathic presentation of a histologic pattern of OP. COP was initially coined as a multidisciplinary diagnosis in 1983 (28), before the description of the same entity under the name "bronchiolitis obliterans OP" in 1985 (29). COP was the recommended term in the 2002 ATS/ERS statement on the classification of the idiopathic interstitial pneumonias (1) and has since remained the preferred terminology (2). "COP" avoids confusion with other terms such as constrictive bronchiolitis (sometimes referred to as constrictive bronchiolitis obliterans or obliterative bronchiolitis), which is a distinct entity from the bronchiolitis obliterans that can occur in some patients with COP (e.g., as a manifestation of chronic graft versus host reaction after transplant). Although "idiopathic OP" would be a reasonable alternative, "COP" has been the recommended term for over 2 decades and remains the preferred term. COP is relatively uncommon, compared with cases where an underlying cause is known, particularly in patients with CTD and drug toxicity (30).

Acute Eosinophilic Pneumonia (AEP)

AEP is an acute eosinophilic lung disease characterized by more than 25–30% eosinophils on BAL or substantial eosinophils present on lung biopsy and typically ground-glass opacification on chest imaging. AEP can be associated with medications, inhalational exposures (especially tobacco smoke), and infections (31, 32). "AEP" is recommended, given the absence of a suggested alternative, with "idiopathic AEP" being appropriate for description of idiopathic cases.

Chronic Eosinophilic Pneumonia (CEP)

Chronic eosinophilic pneumonia (CEP) is a chronic eosinophilic lung disease characterized by more than 25% eosinophils on BAL or

substantial eosinophils present on lung biopsy and typically multifocal consolidation and/or ground-glass opacification on chest imaging. CEP is usually idiopathic and is frequently associated with asthma, with rare association with a variety of other causes (32). "CEP" is recommended, given the absence of a suggested alternative, with "idiopathic CEP" being appropriate for description of idiopathic cases.

Lipoid Pneumonia

Lipoid pneumonia is characterized by lipid-like (lipoid) material filling alveoli and extending into distal airways, with BAL and lung biopsy not typically required for diagnosis (33). Exogenous lipoid pneumonia is caused by aspiration of foreign material (e.g., mineral oil), whereas endogenous lipoid pneumonia is associated with a variety of potential causes, including large airway obstruction, malignancy, infection, inborn errors of metabolism, and immunological diseases. "Lipoid pneumonia" is used most often in the literature to refer to this entity, with "exogenous" and "endogenous" serving as subclassifiers. "Lipoid pneumonitis" is not preferred, as many patients lack a significant inflammatory component. "Cholesterol pneumonia" is too narrow a term, given the different potential causes of this condition.

AMP

AMP is characterized by excessive widespread accumulation of macrophages within alveoli, most commonly in the context of cigarette smoking. "Desquamative interstitial pneumonia (DIP)" was historically used to describe this entity because it was thought that the cells within the alveolar spaces were desquamated pneumocytes; however, these are, instead, alveolar macrophages, and "AMP" is now preferred, as it more accurately represents the underlying pathobiology of disease. "Idiopathic AMP" is recommended for rare cases that are idiopathic (i.e., without a consistent smoking history or other identified cause). "Smoking-related interstitial fibrosis" refers to a pathologic pattern, with "airspace enlargement with fibrosis" also used to refer to frequently associated pathologic findings, whereas "smoking-related ILD" is a broad category that includes heterogeneous forms of smoking-related lung disease.

Respiratory Bronchiolitis ILD (RB-ILD)

RB-ILD is characterized by bronchiolocentric accumulation of pigmented macrophages in airspaces in current or former smokers. The main imaging features including centrilobular ground-glass nodules and patchy ground-glass opacities, which can also be seen incidentally on lung biopsy in patients with subclinical disease (referred to as "RB") (34). RB-ILD is less likely to progress and more likely to improve, compared with AMP (35). RB-ILD has occasionally been referred to in the literature as "idiopathic RB-ILD"; however, it is no longer appropriate to consider this almost exclusively smoking-related entity to be idiopathic. "RB-ILD" is, therefore, preferred over "idiopathic RB-ILD." "Idiopathic RB-ILD" is recommended for rare cases that are idiopathic (i.e., without a consistent smoking history or other identified cause) (36).

Pulmonary Alveolar Proteinosis (PAP)

PAP is a rare syndrome caused by several distinct diseases in which there is abnormal accumulation of (lipo-)proteinaceous material in the lungs, which is often caused by reduced granulocyte–macrophage colony–stimulating factor signaling or abnormal surfactant metabolism (37). The etiology is autoimmune in 90% of adult cases, with hematological diagnoses and inhalational exposures accounting for most of the remainder (38). Although it is a simpler term that conveys the same meaning, there is insufficient justification to use "alveolar proteinosis" rather than the historical precedent of "PAP." "Idiopathic PAP" and "unclassified PAP" have been used for cases without an etiology.

Immune Disorder-related ILDs

CTD-associated ILD/Systemic Autoimmune Rheumatic Disease (SARD)-associated ILD

CTD-ILD describes the presence of ILD in an individual with an underlying CTD, regardless of the underlying CTD subtype or ILD pattern. CTD-ILD could also be viewed as a major phenotype, which encompasses multiple individual CTD subtypes and multiple different ILD patterns. The "CTD" descriptor is the preferred terminology over "collagen vascular disease," given that the underlying disorder is within the connective tissues and the vascular involvement is secondary. "Autoimmune ILD" has also been suggested to represent the systemic process underlying the disease; however, this term is infrequently used and offers little advantage over "CTD-ILD." Further precision in terminology is based on specifying the underlying CTD subtype and/or ILD pattern. For example, "RA-ILD" should be used for ILD secondary to rheumatoid arthritis (RA) with a particular ILD pattern on computed tomography or lung biopsy also labeled if applicable (e.g., "RA-UIP"). "SARD" has been suggested as a replacement for CTD by a recent American College of Rheumatology/American College of Chest Physicians guideline; however, the uptake of this new term (SARD-ILD) is uncertain at this time, and it remains unclear whether "SARD-ILD" will replace "CTD-ILD" (39). Given this recent guideline recommendation, SARD-ILD is also appropriate for use at this time; however, we emphasize the need for the field to coalesce around one of these terms in the near future.

Interstitial Pneumonia with Autoimmune Features (IPAF)

IPAF was proposed in a 2015 ERS/ATS research statement, representing patients with ILD occurring with features that suggest, but are not definitive for, a CTD (40). IPAF remains a research term that is used to further understand this entity. Although "ILD with autoimmune features" would harmonize terminology with other ILDs, the minor semantic change has insufficient justification, given the nearly exclusive use of IPAF in the literature.

Granulomatosis with Polyangiitis (GPA)

GPA is an antineutrophil cytoplasmic antibody (ANCA)–associated necrotizing granulomatous vasculitis predominantly affecting small-to-medium sized vessels and usually involving the upper and lower respiratory tract. Frequent lung involvement includes DAH, nodules/masses, airway disease, and ILD (41). In 2012, the International Chapel Hill Consensus Conference adopted the recommendation of the American College of Rheumatology, the American Society of Nephrology, and European League Against Rheumatism to replace "Wegener's granulomatosis" with "GPA" (42). This change reflects a general trend to replace eponyms with labels that better represent disease biology and/or pathology.

Microscopic Polyangiitis (MPA)

MPA was used in the 1994 Chapel Hill Consensus Conference and 2012 update

to describe a predominantly small-vessel ANCA-associated vasculitis characterized by the presence of hemorrhagic pulmonary capillaritis and glomerulonephritis with an absence of immune complex deposition on immunofluorescence (41–43). MPA was previously thought to be a type of polyarteritis nodosa; however, "MPA" emphasizes the differences from classic polyarteritis nodosa, which is a medium-vessel vasculitis that spares the arterioles and venules.

Eosinophilic Granulomatosis with Polyangiitis (EGPA)

EGPA is an ANCA-associated, small-vessel vasculitis characterized by asthma and marked peripheral eosinophilia. "Churg-Strauss syndrome" was used historically to describe this disorder, with "EGPA" being recommended in the 2012 revised International Chapel Hill Consensus Conference Nomenclature of Vasculitides, prioritizing histopathological accuracy over the use of eponyms (42). "Allergic angiitis and granulomatosis" and "allergic granulomatosis" have also been suggested to emphasize the immunological component of this disease, but with limited uptake in the literature and an unclear meaning of "allergic."

Anti-Glomerular Basement Membrane (Anti-GBM) Disease

Anti-GBM disease is a small-vessel vasculitis characterized by antibodies against basement membrane antigens, frequently causing both alveolar hemorrhage and glomerulonephritis. Although the pathogenic antibodies of anti-GBM disease react to GBM antigens as well as the pulmonary capillaries, "anti-GBM disease" is considered the most appropriate term for this disease, which is consistent with the recommendations made in the 2012 International Chapel Hill Consensus Conference (42). "Anti-GBM antibody disease" is inaccurate, as use of both "anti" and "antibody" creates an inappropriate double negative. The change away from "Goodpasture's syndrome" and "Goodpasture's disease" is part of a general trend to replace eponyms with labels that better represent the disease biology and/or pathology.

Inflammatory Bowel Disease-associated ILD (IBD-ILD)

IBD-ILD can rarely occur with either ulcerative colitis or Crohn's disease. Although OP is the most common presentation (44), a variety of other interstitial and alveolar filling patterns can be seen, including NSIP, UIP, DAD, and eosinophilic pneumonia, with some patients also presenting with airway disease. "IBD-ILD" is preferred to the alternative of "IBD-associated lung disease" when referring to patients with interstitial involvement, maintaining consistency with other entities that include ILD as a root term.

Granulomatous-Lymphocytic ILD (GL-ILD)

GL-ILD is primarily a complication of common variable immunodeficiency (CVID) but can also be seen with other forms of immunodeficiency, CTLA-4 deficiency, or multiple myeloma in adults, or with a variety of primary immunodeficiencies in children (45–47). Limiting terminology by including CVID in the name (i.e., "CVID-ILD") is, therefore, inaccurate because there are causes of this disease other than CVID. Conversely, other forms of lung disease can also be seen in CVID (e.g., other ILDs, bronchiectasis). "Granulomatous-lymphocytic lung disease" captures the full variety of lung manifestations, including granulomatous disease, follicular bronchiolitis, ILD, lymphoid hyperplasia, and bronchiectasis; however, "GL-ILD" is preferred when referring to patients with predominant interstitial involvement, maintaining consistency with other entities that include ILD as a root term.

IgG4-related ILD

IgG4-related disease is typically a multisystem disorder characterized by lymphoplasmacytic infiltration with abundant IgG4-positive plasma cells, including within the lung interstitium, airways, air spaces, intrathoracic lymph nodes, and pleura (48). The propensity for multisystem involvement has led to use of multiple terms that often denote the organ(s) that are principally affected (e.g., lymphoplasmacytic sclerosing pancreatitis). Although infiltration by IgG4-positive plasma cells in the chest is not confined to the interstitium, the term "IgG4-related ILD" remains preferable to "IgG4-related lung disease" and "hyper–IgG4-related lung disease" when referring to the presence of disease affecting the interstitium, maintaining consistency with other entities that include ILD as a root term.

Exposure-related/Secondary

HP

HP is an inflammatory and/or fibrotic disease affecting the lung parenchyma and small airways that results from an immune-mediated reaction provoked by an inhaled antigen in susceptible individuals (18, 19). "HP" is preferred over "hypersensitivity pneumonia," given that the minor semantic change to "pneumonia" does not justify deviation from historical preference of "pneumonitis." The historical term "extrinsic allergic alveolitis" is not favored as the disease is not a true allergy and involves the bronchioles and interstitium as well as the alveoli. "HP" as the preferred term is consistent with clinical practice guidelines from multiple societies. Patients with a specific cause identified should be referred to as "'x'-associated HP" (e.g., "bird-associated HP").

Hot Tub Lung

Hot tub lung represents a hypersensitivity reaction to *Mycobacterium avium* complex resulting from recurrent exposure to aerosolized organisms growing in water sources; most commonly, hot tubs. Hot tub lung is radiologically and pathologically distinct from other common causes of HP and is, thus considered an independent entity (49–51). "Hot tub lung" is preferred over "hot tub lung disease" on the basis of historical precedence. "Hot tub lung" is also preferred over both "hot tub pneumonitis" and "hot tub–associated HP," with these alternatives inappropriately implying similarity with other causes of HP.

Flock Worker's Lung

Flock worker's lung results from exposure over many years to nylon flock, a short monofilament fiber used in both industrial and domestic applications (52). Flock worker's lung is primarily a historical entity that is rarely encountered, given the changes in manufacturing processes (53, 54). "Flock worker's lung" is preferred over "flock lung" or "nylon-flock associated ILD," as it is the specific flock manufacturing approach and not the use of flock itself that is associated with disease. "Flock worker's pneumoconiosis" inappropriately suggests similarity to other pneumoconioses (e.g., asbestos, silicosis).

Silicosis

Silica- or silicate-induced diseases can present as acute silicosis (silicoproteinosis)

in patients with short-term, high-intensity exposure or more chronically with prolonged exposure as simple (nodular) silicosis or progressive massive fibrosis (55–57). Silicosis is used to refer to patients with both simple silicosis and complicated silicosis/progressive massive fibrosis. Including "pneumoconiosis" in the terminology (e.g., "pneumoconiosis due to silica," "silica pneumoconiosis," and "silicopneumoconiosis") adds complexity without additional specificity or accuracy and inappropriately suggests that the disease only happens in association with occupational exposure. The preference for "silicosis" is consistent with historical precedent and adequately reflects the disease process and etiology. Some patients with multiple exposures (e.g., silica plus coal) have "mixed dust pneumoconiosis."

Asbestosis

Asbestosis is an occupational lung disease characterized by lower lobe–predominant fibrosis caused by prolonged inhalation of asbestos fibers (56–58). The histopathologic and radiologic manifestations of asbestosis are similar to other types of pulmonary fibrosis (e.g., IPF), with additional signs of asbestos exposure such as calcified pleural plaques typically present. "Asbestosis" adequately reflects the etiology and disease process and is also consistent with both historical precedent and previous consensus statements (57, 58). Including "pneumoconiosis" (e.g., "pneumoconiosis due to asbestos," "asbestos pneumoconiosis) adds complexity without improving specificity or accuracy and inappropriately suggests that the disease only occurs in association with occupational exposure. "Asbestos-related ILD" carries similar meaning to "asbestosis" but has not been frequently used. The term "asbestosis" is not used to refer to other pulmonary complications arising from asbestos exposure (e.g., asbestosis does not encapsulate pleural disease or mesothelioma).

Coal Pneumoconiosis

A variety of lung diseases can be caused by inhalation of high-carbon coal dust, most frequently but not always associated with more than 20 years of coal mining (56, 57). The deposition of coal dust results in dust-laden macrophages around bronchioles (coal macules) and may also cause focal areas of emphysema and, frequently, airflow obstruction (59). When coal is considered an isolated exposure with consequent interstitial changes, the term "coal pneumoconiosis" is preferred. The use of both "worker's" and "pneumoconiosis" within the term "coal worker's pneumoconiosis" is redundant, whereas "pneumoconiosis due to coal" adds complexity without improving specificity or accuracy. There has been a resurgence of rapidly progressive lung disease in coal workers during the past 2 decades, caused by concomitant silica exposure, which is associated with progressive massive fibrosis (60, 61). These workers commonly carry a diagnosis of "mixed dust pneumoconiosis," but this is not an appropriate term when coal is considered the primary exposure of relevance. Coal pneumoconiosis should not be used to refer to non-ILD manifestations of coal exposure (e.g., isolated emphysema).

Berylliosis

Berylliosis is a nonnecrotizing granulomatous inflammatory disease characterized by T cell sensitization to inhaled beryllium, a metal dust most often used in electronics, ceramics, aerospace, and defense industries (56). Exposure to beryllium can cause beryllium sensitization, detected by a beryllium lymphocyte proliferation test, with some patients developing radiologic and pathologic features indistinguishable from sarcoidosis and a minority having progressive fibrosis. "Berylliosis" is the preferred term, given the spectrum from acute to chronic forms. Including "pneumoconiosis" inappropriately suggests that the disease only happens in association with occupational exposure. Furthermore, although berylliosis is predominately a pulmonary disease, it may also result in granuloma deposition in the liver and it is therefore not exclusively a pneumoconiosis.

Hard Metal Pneumoconiosis

Hard metal pneumoconiosis results from inhalational exposure to the hard metals tungsten carbide and cobalt. It is characterized by the pattern of giant cell interstitial pneumonia, often resembling HP or presenting with ground-glass opacification or small nodules (62), with some patients having episodes of work-related subacute disease and others evolving to lung fibrosis (63, 64). "Hard metal pneumoconiosis" is preferred over other terms that are overly specific to a given exposure ("'x' pneumoconiosis") or cell type/pattern ("giant cell interstitial pneumonia") that lack sufficient justification to support change from historical precedence ("hard metal-associated ILD," "hard metal-associated lung injury") or that add complexity with little additional benefit ("pneumoconiosis due to 'x' hard metal").

Drug-associated ILD

Drug-associated ILD can present with a variety of interstitial and alveolar filling reactions, frequently including multiple and, sometimes, overlapping or concurrent patterns (65, 66). The historical term of "drug-induced lung disease" or "drug-related lung disease" less adequately captured the predilection for the lung interstitium and did not acknowledge the frequent diagnostic uncertainty resulting from other potential causes that frequently coexist. The terms "medication-associated ILD," "drug-associated lung injury," and "medication-associated lung injury" have been advocated but with limited uptake in the literature, failure to convey the typically widespread extent of disease, or deemphasis of the relatively high likelihood of progression even after cessation of the culprit drug. "Drug-related pneumonitis" is commonly used in oncology but with limited use in other settings (65, 66). It will become increasingly important to align terminology with the oncologic field, given the high frequency of drug-associated ILD with new cancer medications.

Radiotherapy-associated Lung Injury

Radiotherapy-associated lung injury can occur along a spectrum of primarily inflammation (acute pneumonitis) to primarily chronic fibrosis. Radiotherapy causing OP, either inside or outside the radiation field, is considered a distinct entity and is, instead, referred to as "OP secondary to radiotherapy" (67). "Radiotherapy-associated lung injury" is the preferred term for the local injury pattern over "radiotherapy-associated ILD," "radiotherapy-induced ILD," and "radiotherapy-induced lung injury." This preferred term better conveys the frequent diagnostic uncertainty (i.e., using "associated rather than "induced") and reflects the low potential for ongoing "disease" progression in patients with more focal abnormality. "Radiotherapy" is the preferred term over "radiation," because these manifestations occur after radiotherapy and not with the radiation doses used in diagnostic radiology or nuclear medicine.

Post-ARDS Lung Injury

Lung injury can occur in association with any cause of ARDS (23), most notably after

severe pneumonia. This typically presents with rapid development of lung fibrosis during the initial acute illness, typically characterized by DAD but with subsequent progressive fibrosis thought to be less common compared with other causes of pulmonary fibrosis. "Post-ARDS lung injury" is preferred over "post-ARDS ILD" to reflect the low potential for ongoing disease progression and greater likelihood of stability or improvement that is typically observed after an acute isolated injury.

Post–Infectious Lung Injury

Like post-ARDS fibrosis, lung injury can occur after any severe lung infection, regardless of whether the initial event met criteria for ARDS, which is usually limited to areas of initial infection and with low risk of ongoing progressive fibrosis. "Post–infectious lung injury" is preferred over "post–infectious ILD" to reflect the low potential for ongoing disease progression and greater likelihood of stability or improvement that is typically observed after an acute isolated infectious injury. Notably, this diagnosis is distinct from post–infectious OP, which carries a unique presentation, imaging findings, management approach, and prognosis.

Neoplasms Presenting as ILD

Pulmonary Langerhans Cell Histiocytosis (PLCH)

Pulmonary Langerhans cell histiocytosis (PLCH) is a distinct form of histiocytosis that develops when an abundance of monoclonal CD1a-positive dendritic cells (Langerhans cells) proliferates within and damages the bronchioles and alveolar interstitium (68). PLCH almost exclusively affects the lungs of young adult smokers, resulting in solid and/or cavitating small nodules primarily in early disease and thick- or thin-walled cysts of varying size and shape in advanced disease (24). The Histiocyte Society proposed diagnostic criteria for PLCH in 1989, and it remains consensus that "PLCH" is the most appropriate term to refer to this disease, despite eponyms falling out of favor for other entities (69). Langerhans cells have distinct surface characteristics compared with other types of histiocytes, as would be implied by an alternative term of "pulmonary/systemic histiocytosis" (70). The "X" within "histiocytosis-X" was initially used to convey the uncertainty about the disease and its pathogenesis; however, this term is no longer appropriate, given what is known about the disease. "Eosinophilic granuloma" is a misnomer since eosinophils are not a prominent or consistent finding. "Single-system PLCH" has also been suggested (71), but inclusion of both "single-system" and "pulmonary" is considered unnecessary.

Erdheim–Chester Disease

Erdheim–Chester disease is a multisystem disease characterized by abnormal proliferation of lipid laden histiocytes that infiltrate multiple organs and tissues, including bones, pituitaries, eyes, brain, and lungs. Pulmonary involvement may cause pulmonary fibrosis with smooth symmetric reticulation and interlobular thickening, areas of centrilobular nodularity and ground-glass opacity, and pleural or subpleural thickening. It is typically confirmed by histopathology in the appropriate clinical/radiologic setting. The major justification for the term "Erdheim–Chester disease" is that it is currently in widespread and consistent use. The alternative term, "polyostotic sclerosing histiocytosis," fails to capture the breadth of systemic involvement and has limited uptake in the literature. The alternative term, "non–Langerhans histiocytosis," refers to a series of related disorders such as dermatofibroma and juvenile xanthogranuloma and is not limited merely to Erdheim–Chester disease. Despite being an eponym and having other limitations, "Erdheim–Chester disease" remains the preferred term for this disease, as there is currently no appropriate alternative suggested in the literature.

Lymphangioleiomyomatosis (LAM)

LAM is characterized by progressive formation of thin-walled cysts in the lungs caused by proliferation of atypical smooth muscle cells (LAM cells) and encountered predominantly in women (24, 72–75). LAM can occur in patients with tuberous sclerosis complex (TSC), which is referred to as TSC-LAM, or as sporadic LAM in those without TSC. Extrapulmonary manifestations such as renal angiomyolipomas and retroperitoneal lymphangioleiomyomas can be seen in both groups, whereas dermatologic and neurologic stigmata are seen only in those with TSC-LAM. "LAM" is generally representative of disease pathobiology, and there is no alternative term suggested in the literature.

ILDs Induced by Lymphoproliferative Disease

Pulmonary Amyloidosis

Pulmonary amyloidosis is caused by extracellular deposition of misfolded proteins in insoluble β-sheet (amyloid) fibrils that show a characteristic appearance of green birefringence with Congo red dye under polarized light on microscopy, with diagnosis confirmed by immunohistochemistry and/or mass spectrometry (76, 77). Pulmonary manifestations range from asymptomatic nodules to severe ILD, a form usually associated with multiorgan involvement. Amyloidosis is further subtyped by the specific precursor protein. The majority of cases localized to the lung are AL-type amyloid, which results from the accumulation of protein derived from immunoglobulin light chain fragments and may be associated with B-cell neoplasms. Pulmonary involvement by systemic amyloidoses may also occur, comprising AA-type, ATTR-type, or AL-type, with different patterns of lung involvement (78). AL amyloid results from the accumulation of protein derived from immunoglobulin light chain fragments and accounts for most cases with lung involvement. There is no alternative term suggested for "pulmonary amyloidosis."

Light Chain Deposition Disease (LCCD)

LCDD is caused by the abnormal production and tissue accumulation of nonorganized monoclonal immunoglobulin light chains, typically consisting of kappa light chains (79). The light chain deposits have a nonfibrillar structure and do not bind the Congo red histochemical stain; diagnosis is made using immunofluorescence, electron microscopy, or mass spectrometry. Pulmonary involvement consists of nodular, cystic, and diffuse forms. "LCDD" is preferred over "non-amyloid LCDD," as the shorter and simpler term implicitly incorporates the concept that the abnormal light chain deposits are not organized in the fibrillar structure that is characteristic of amyloid protein.

Pulmonary Lymphomatoid Granulomatosis

Lymphomatoid granulomatosis is a rare, Epstein-Barr virus–associated, B-cell lymphoproliferative disorder that frequency affects the lungs, central nervous system, and skin. Pulmonary lymphomatoid granulomatosis is characterized by

lymphocytic invasion of vascular walls on biopsy and multifocal pulmonary vasculocentric nodular lesions (80, 81). Pulmonary lymphomatoid granulomatosis is considered a distinct clinical diagnosis, despite potential clinical and morphological overlap with other angiocentric immunoproliferative abnormalities such as angiocentric lymphoma and angiocentric immunoproliferative lesions. There is no alternative term suggested for "pulmonary lymphomatoid granulomatosis."

Castleman Disease-associated ILD

Castleman disease is a lymphoproliferative disorder affecting more than one lymph node group (82). "Castleman disease–associated ILD" refers to the subgroup of patients with Castleman disease who have ILD, typically characterized by bronchovascular thickening, interlobular thickening, and cysts (81, 83, 84). It is typically confirmed by histopathology in the appropriate clinical/radiologic setting. "Castleman disease–associated ILD" is preferred over "multicentric Castleman disease" when referring to the presence of ILD in this context, given the greater specificity of this term for the presence of ILD. Although there is intent to eliminate eponyms, there is currently no appropriate alternative suggested in the literature.

Congenital/Genetic

Folliculin Deficiency-associated ILD

Folliculin deficiency is a rare autosomal dominant disorder caused by germline mutations in the *FLCN* tumor suppressor gene that encodes the folliculin protein (85). Folliculin deficiency is characterized by cystic lung disease, recurrent pneumothoraces, skin lesions (cutaneous fibrofolliculomas), and kidney tumors of various histological types (24, 86). "Folliculin deficiency" was referred to as "Birt-Hogg-Dubé syndrome" after the three physicians who originally described this entity (87), but "folliculin deficiency" is now suggested as the preferred term to better reflect the pathogenesis of disease. "Folliculin deficiency–associated ILD" is preferred over "Birt-Hogg-Dubé syndrome" when referring to the presence of ILD in this context.

Neurofibromatosis-associated ILD

Neurofibromatosis refers to two rare autosomal dominant disorders that result from mutations in the NF1 and NF2 tumor suppressor genes. Pulmonary manifestations may include upper lobe predominant cysts, bullae, and ground-glass opacities and, rarely, bilateral basal reticulation (88, 89). Lung biopsy shows interstitial fibrosis, with deposition of collagen alternating with relatively normal areas of lung, sometimes also including septal thickening and increased cellularity. "Neurofibromatosis-associated ILD" is preferred to the alternative of "neurofibromatosis-associated lung disease" when referring to patients with lung involvement of the interstitium, maintaining consistency with other diagnoses that include ILD as a root term.

Acid Sphingomyelinase Deficiency (ASMD)-associated ILD

ASMD is a rare autosomal recessive genetic disorder caused by mutations in the sphingomyelin phosphodiesterase 1 (*SMPD1*) gene and historically known as Niemann-Pick disease (90, 91). Niemann-Pick disease was traditionally classified into Type A, which is typically fatal in early childhood, and Type B, which typically presents with chronic progressive multisystem disease, including ILD that often manifests with nonspecific ground-glass and interlobular septal thickening. A third type (Type C) is a distinct genetic lysosomal storage disorder. ASMD encompasses Niemann-Pick Types A and B, excluding Type C. ASMD is the preferred term because it clearly describes the biology and, by definition, excludes the distinct Niemann-Pick Type C, with "ASMD-ILD," therefore, preferred when referring to the presence of ILD in this context.

α-Galactosidase A Deficiency-associated ILD

α-galactosidase A deficiency is an X-linked disorder resulting from the accumulation of glycosphingolipids in multiple organs, primarily affecting the heart, kidneys, skin, central nervous system, and less frequently the lungs, where obstructive manifestations are more common than restrictive (91–94). The "α-galactosidase A deficiency" is preferred to that of "Fabry disease," given that this disorder is secondary to monogenic mutations in the *GLA* gene encoding α-galactosidase, a lysosomal hydrolase, and given the preference for adopting pathobiologically relevant terms over historical eponyms. "α-galactosidase A deficiency–associated ILD" is, therefore, preferred over "Fabry disease" when referring to the presence of ILD in this context. "Angiokeratoma corporis diffusum" describes only the dermatologic manifestations and is, therefore, also not considered a suitable option.

Glucocerebrosidase Deficiency–associated ILD

Glucocerebrosidase deficiency is a lysosomal storage disease that can affect multiple organs, including spleen, liver, bones, and bone marrow (91). A minority of patients have pulmonary manifestations, including ILD and pulmonary hypertension. ILD typically presents with nonspecific ground-glass and interlobular septal thickening. BAL shows lipid-laden macrophages, with lung biopsy showing foamy intraalveolar and interstitial histiocytes, often with accompanying fibrosis and lymphocyte infiltrates. "Glucocerebrosidase deficiency–associated ILD" is preferred over "Gaucher disease" when referring to the presence of ILD in this context, given the preference for adopting pathobiologically relevant terms over historical eponyms.

Congenital Pulmonary Lymphangiectasis

Lymphangiectasis refers to dilation of lymphatics without proliferation of lymphatic vessels (in contrast to lymphangiomatosis where there is proliferation) (95). This is most commonly congenital, with secondary lymphangiectasis found in Waldmann disease and lymphatic obstruction. The term "congenital pulmonary lymphangiectasis" is preferred over "primary pulmonary lymphangiectasis" to better capture the congenital basis of the disease.

Diffuse Pulmonary Lymphangiomatosis

Lymphangiomatosis is a rare disease characterized by diffuse lymphangiomas within lymphatics, with this uncontrolled lymphatic vessel proliferation driven by vascular endothelial growth factor (96). Possible imaging findings include smooth interlobular septal thickening, patchy ground-glass opacification, pleural effusion, and smooth pleural thickening (97), with lung biopsy similarly showing abnormality primarily along the interlobular septa and pleura (98). "Diffuse pulmonary lymphangiomatosis" is preferred over "pulmonary lymphangiomatosis" and "lymphangiomatosis" to better reflect that lymphatic proliferation is diffuse in the lung, and it further avoids confusion with lymphangioleiomyomatosis.

Other

Sarcoidosis

Sarcoidosis is a multisystem disease of uncertain etiology that is characterized by nonnecrotizing epithelioid granulomas most frequently affecting the lymph nodes, lungs, skin, and eyes (99). Pulmonary involvement occurs most commonly with distinct clinical and radiologic phenotypes, with variable disease trajectories and outcomes (100). "Sarcoidosis" is the preferred term for this entity, distinguishing the primary diagnosis from secondary sarcoid-like reactions that can occur because of a variety of causes (e.g., medication adverse effects).

Pulmonary Alveolar Microlithiasis

Pulmonary alveolar microlithiasis is caused by an inherited or more commonly spontaneous mutation in the *SLC34A2* gene that affects function of the Type IIb sodium phosphate transporter in Type II alveolar pneumocytes, impairing clearance of phosphate from alveolar spaces that subsequently binds calcium. Pulmonary alveolar microlithiasis has a characteristic and progressive appearance on imaging with numerous tiny calcifications in a subpleural and bronchovascular distribution, with lung biopsy showing microliths in the alveolar airspaces, interlobular septa, bronchovascular bundles, and pleura (101–104). "Pulmonary alveolar microlithiasis" is preferred over "alveolar microlithiasis," given its historical precedence.

Idiopathic Diffuse Pulmonary Ossification (DPO)

DPO is characterized by formation of metaplastic bone in the pulmonary parenchyma with associated high-density abnormalities identified on chest imaging. It is often associated with underlying cardiac or pulmonary disease but is considered idiopathic when identified in isolation (105–107). The dendriform subtype of DPO typically occurs in men with risk factors for aspiration (108) but without other evidence of lung fibrosis, and it corresponds histologically to cicatricial OP (107, 109). A nodular, usually nondendriform, pattern of ossification occurs in up to 20% of patients with pulmonary fibrosis (106). "DPO" is preferred over "idiopathic DPO" when occurring concomitantly with other ILDs, wherea "idiopathic DPO" is reserved for the rare idiopathic cases.

Conclusions

The rarity of individual ILD subtypes indicates the need to generate new knowledge through multicenter collaboration; however, direct comparisons across studies and pooling of distinct cohorts is often limited by inconsistent terminology and classification approaches. Using a modified Delphi approach, we use agreement between experts to propose standardized terminology for ILD clinical diagnoses and major phenotypes. Standardizing the terminology used for ILD and translating this knowledge to a broad community will accelerate clinically relevant insights and biological discovery by facilitating communication among a variety of stakeholders. We recognize that recommended terms may be challenging to implement universally but emphasize the importance of the broader ILD community adopting a standard approach to terminology as presented here. This effort will also require updating of what are frequently outdated terms and diagnostic codes that are still used by many organizations, including codes from the International Classification of Diseases. This evolution will further need not only clear mapping from previous to new terminology, including the addition of new diagnoses, but also incorporation of these recommended standards to ensure accurate data ascertainment in electronic health records. Although this document represents a major step toward our communal goal of improving care for patients with ILD, this document is also intended to be both flexible and iterative, requiring updates as our understanding of ILD evolves. ■

Author disclosures are available with the text of this article at www.atsjournals.org.

References

1. American Thoracic Society/European Respiratory Society. American Thoracic Society/European Respiratory Society international multidisciplinary consensus classification of the idiopathic interstitial pneumonias. *Am J Respir Crit Care Med* 2002;165:277–304.
2. Travis WD, Costabel U, Hansell DM, King TE, Lynch DA, Nicholson AG, *et al.*; ATS/ERS Committee on Idiopathic Interstitial Pneumonias. An official American Thoracic Society/European Respiratory Society statement: update of the international multidisciplinary classification of the idiopathic interstitial pneumonias. *Am J Respir Crit Care Med* 2013; 188:733–748.
3. Hansell DM, Bankier AA, MacMahon H, McLoud TC, Muller NL, Remy J. Fleischner Society: glossary of terms for thoracic imaging. *Radiology* 2008;246:697–722.
4. Bankier AA, MacMahon H, Colby T, Gevenois PA, Goo JM, Leung ANC, *et al.* Fleischner Society: glossary of terms for thoracic imaging. *Radiology* 2024;310:e232558.
5. Diamond IR, Grant RC, Feldman BM, Pencharz PB, Ling SC, Moore AM, *et al.* Defining consensus: a systematic review recommends methodologic criteria for reporting of Delphi studies. *J Clin Epidemiol* 2014;67:401–409.
6. Lim RK, Humphreys C, Morisset J, Holland AE, Johannson KA; O2 Delphi Collaborators. Oxygen in patients with fibrotic interstitial lung disease: an international Delphi survey. *Eur Respir J* 2019;54:1900421.
7. Hatabu H, Hunninghake GM, Richeldi L, Brown KK, Wells AU, Remy-Jardin M, *et al.* Interstitial lung abnormalities detected incidentally on CT: a position paper from the Fleischner Society. *Lancet Respir Med* 2020;8: 726–737.
8. Raghu G, Remy-Jardin M, Richeldi L, Thomson CC, Inoue Y, Johkoh T, *et al.* Idiopathic pulmonary fibrosis (an update) and progressive pulmonary fibrosis in adults: an official ATS/ERS/JRS/ALAT clinical practice guideline. *Am J Respir Crit Care Med* 2022;205:e18–e47.
9. Flaherty KR, Wells AU, Cottin V, Devaraj A, Walsh SLF, Inoue Y, *et al.*; INBUILD Trial Investigators. Nintedanib in progressive fibrosing interstitial lung diseases. *N Engl J Med* 2019;381:1718–1727.
10. Collard HR, Ryerson CJ, Corte TJ, Jenkins G, Kondoh Y, Lederer DJ, *et al.* Acute exacerbation of idiopathic pulmonary fibrosis. an international working group report. *Am J Respir Crit Care Med* 2016;194:265–275.
11. Wong AW, Liang J, Cottin V, Ryerson CJ. Diagnostic features in combined pulmonary fibrosis and emphysema: a systematic review. *Ann Am Thorac Soc* 2020;17:1333–1336.
12. Cottin V, Selman M, Inoue Y, Wong AW, Corte TJ, Flaherty KR, *et al.* Syndrome of combined pulmonary fibrosis and emphysema: an official ATS/ERS/JRS/ALAT research statement. *Am J Respir Crit Care Med* 2022;206:e7–e41.
13. Borie R, Kannengiesser C, Antoniou K, Bonella F, Crestani B, Fabre A, *et al.* European Respiratory Society statement on familial pulmonary fibrosis. *Eur Respir J* 2023;61:2201383.
14. Lynch DA, Sverzellati N, Travis WD, Brown KK, Colby TV, Galvin JR, *et al.* Diagnostic criteria for idiopathic pulmonary fibrosis: a Fleischner Society white paper. *Lancet Respir Med* 2018;6:138–153.
15. Raghu G, Remy-Jardin M, Myers JL, Richeldi L, Ryerson CJ, Lederer DJ, *et al.*; American Thoracic Society, European Respiratory Society,

Japanese Respiratory Society, and Latin American Thoracic Society. Diagnosis of idiopathic pulmonary fibrosis. An official ATS/ERS/JRS/ALAT clinical practice guideline. *Am J Respir Crit Care Med* 2018;198: e44–e68.
16. Katzenstein AL, Fiorelli RF. Nonspecific interstitial pneumonia/fibrosis. *Am J Surg Pathol* 1994;18:136–147.
17. Travis WD, Hunninghake G, King TE, Lynch DA, Colby TV, Galvin JR Jr, *et al.* Idiopathic nonspecific interstitial pneumonia: report of an American Thoracic Society project. *Am J Respir Crit Care Med* 2008;177:1338–1347.
18. Fernández Pérez ER, Travis WD, Lynch DA, Brown KK, Johannson KA, Selman M, *et al.* Diagnosis and evaluation of hypersensitivity pneumonitis: CHEST guideline and expert panel report. *Chest* 2021; 160:e97–e156.
19. Raghu G, Remy-Jardin M, Ryerson CJ, Myers JL, Kreuter M, Vasakova M, *et al.* Diagnosis of hypersensitivity pneumonitis in adults. An official ATS/JRS/ALAT clinical practice guideline. *Am J Respir Crit Care Med* 2020;202:e36–e69.
20. Marinescu D-C, Hague CJ, Muller NL, Murphy D, Churg A, Wright JL, *et al.* Integration and application of radiologic patterns from clinical practice guidelines on idiopathic pulmonary fibrosis and fibrotic hypersensitivity pneumonitis. *Chest* 2023;164:1466–1475.
21. Mooney JJ, Elicker BM, Urbania TH, Agarwal MR, Ryerson CJ, Nguyen MLT, *et al.* Radiographic fibrosis score predicts survival in hypersensitivity pneumonitis. *Chest* 2013;144:586–592.
22. Amitani R, Niimi A, Kuze F. Idiopathic pulmonary upper lobe fibrosis (IPUF) [in Japanese]. *Kokyu* 1992;11:693–699.
23. Matthay MA, Arabi Y, Arroliga AC, Bernard G, Bersten AD, Brochard LJ, *et al.* A new global definition of acute respiratory distress syndrome. *Am J Respir Crit Care Med* 2024;209:37–47.
24. Johnson SR, Shaw DE, Avoseh M, Soomro I, Pointon KS, Kokosi M, *et al.* Diagnosis of cystic lung diseases: a position statement from the UK Cystic Lung Disease Rare Disease Collaborative Network. *Thorax* 2024;79:366–377.
25. Fraune C, Churg A, Yi ES, Khoor A, Kelemen K, Larsen BT, *et al.* Lymphoid interstitial pneumonia (LIP) revisited: a critical reappraisal of the histologic spectrum of "radiologic" and "pathologic" LIP in the context of diffuse benign lymphoid proliferations of the lung. *Am J Surg Pathol* 2023;47:281–295.
26. Guler SA, Ellison K, Algamdi M, Collard HR, Ryerson CJ. Heterogeneity in unclassifiable interstitial lung disease. A systematic review and meta-analysis. *Ann Am Thorac Soc* 2018;15:854–863.
27. Ryerson CJ, Corte TJ, Lee JS, Richeldi L, Walsh SLF, Myers JL, *et al.* A standardized diagnostic ontology for fibrotic interstitial lung disease. an international working group perspective. *Am J Respir Crit Care Med* 2017;196:1249–1254.
28. Davison AG, Heard BE, McAllister WA, Turner-Warwick ME. Cryptogenic organizing pneumonitis. *Q J Med* 1983;52:382–394.
29. Epler GR, Colby TV, McLoud TC, Carrington CB, Gaensler EA. Bronchiolitis obliterans organizing pneumonia. *N Engl J Med* 1985;312: 152–158.
30. Cherian SV, Patel D, Machnicki S, Naidich D, Stover D, Travis WD, *et al.* Algorithmic approach to the diagnosis of organizing pneumonia: a correlation of clinical, radiologic, and pathologic features. *Chest* 2022; 162:156–178.
31. De Giacomi F, Vassallo R, Yi ES, Ryu JH. Acute eosinophilic pneumonia. Causes, diagnosis, and management. *Am J Respir Crit Care Med* 2018;197:728–736.
32. Cottin V. Eosinophilic lung diseases. *Immunol Allergy Clin North Am* 2023;43:289–322.
33. Betancourt SL, Martinez-Jimenez S, Rossi SE, Truong MT, Carrillo J, Erasmus JJ. Lipoid pneumonia: spectrum of clinical and radiologic manifestations. *AJR Am J Roentgenol* 2010;194:103–109.
34. Wells AU, Nicholson AG, Hansell DM. Challenges in pulmonary fibrosis · 4: smoking-induced diffuse interstitial lung diseases. *Thorax* 2007;62: 904–910.
35. Nakanishi M, Demura Y, Mizuno S, Ameshima S, Chiba Y, Miyamori I, *et al.* Changes in HRCT findings in patients with respiratory bronchiolitis-associated interstitial lung disease after smoking cessation. *Eur Respir J* 2007;29:453–461.
36. Fraig M, Shreesha U, Savici D, Katzenstein AL. Respiratory bronchiolitis: a clinicopathologic study in current smokers, ex-smokers, and never-smokers. *Am J Surg Pathol* 2002;26:647–653.
37. McCarthy C, Bonella F, O'Callaghan M, Dupin C, Alfaro T, Fally M, *et al.* European Respiratory Society guidelines for the diagnosis and management of pulmonary alveolar proteinosis. *Eur Respir J* 2024;64: 2400725.
38. Inoue Y, Trapnell BC, Tazawa R, Arai T, Takada T, Hizawa N, *et al.*; Japanese Center of the Rare Lung Diseases Consortium. Characteristics of a large cohort of patients with autoimmune pulmonary alveolar proteinosis in Japan. *Am J Respir Crit Care Med* 2008;177: 752–762.
39. Johnson SR, Bernstein EJ, Bolster MB, Chung JH, Danoff SK, George MD, *et al.* 2023 American College of Rheumatology (ACR)/American College of Chest Physicians (CHEST) guideline for the treatment of interstitial lung disease in people with systemic autoimmune rheumatic diseases. *Arthritis Rheumatol* 2024;76:1182–1200.
40. Fischer A, Antoniou KM, Brown KK, Cadranel J, Corte TJ, Du Bois RM, *et al.*; "ERS/ATS Task Force on Undifferentiated Forms of CTD-ILD". An official European Respiratory Society/American Thoracic Society research statement: interstitial pneumonia with autoimmune features. *Eur Respir J* 2015;46:976–987.
41. Villeneuve T, Faguer S, Collot S, Pugnet G, Prevot G. HRCT imaging of pulmonary involvement in granulomatosis with polyangiitis and microscopic polyangiitis at disease onset and during follow-up. *Semin Arthritis Rheum* 2023;63:152307.
42. Jennette JC, Falk RJ, Bacon PA, Basu N, Cid MC, Ferrario F, *et al.* 2012 revised International Chapel Hill Consensus Conference nomenclature of vasculitides. *Arthritis Rheum* 2013;65:1–11.
43. Jennette JC, Falk RJ, Andrassy K, Bacon PA, Churg J, Gross WL, *et al.* Nomenclature of systemic vasculitides. Proposal of an international consensus conference. *Arthritis Rheum* 1994;37:187–192.
44. Massart A, Hunt DP. Pulmonary manifestations of inflammatory bowel disease. *Am J Med* 2020;133:39–43.
45. Hurst JR, Verma N, Lowe D, Baxendale HE, Jolles S, Kelleher P, *et al.* British Lung Foundation/United Kingdom Primary Immunodeficiency Network consensus statement on the definition, diagnosis, and management of granulomatous-lymphocytic interstitial lung disease in common variable immunodeficiency disorders. *J Allergy Clin Immunol Pract* 2017;5:938–945.
46. Bintalib HM, Davidsen JR, Van de Ven AAJM, Goddard S, Burns SO, Warnatz K, *et al.* Current practices and considerations in lung biopsy for suspected granulomatous-lymphocytic interstitial lung disease: a clinician survey. *Respiration* 2024;103:692–700.
47. Galant-Swafford J, Catanzaro J, Achcar RD, Cool C, Koelsch T, Bang TJ, *et al.* Approach to diagnosing and managing granulomatous-lymphocytic interstitial lung disease. *EClinicalMedicine* 2024;75: 102749.
48. Stone JH, Zen Y, Deshpande V. IgG4-related disease. *N Engl J Med* 2012;366:539–551.
49. Hanak V, Kalra S, Aksamit TR, Hartman TE, Tazelaar HD, Ryu JH. Hot tub lung: presenting features and clinical course of 21 patients. *Respir Med* 2006;100:610–615.
50. Hartman TE, Jensen E, Tazelaar HD, Hanak V, Ryu JH. CT findings of granulomatous pneumonitis secondary to *Mycobacterium avium-intracellulare* inhalation: "hot tub lung". *AJR Am J Roentgenol* 2007; 188:1050–1053.
51. Barnes H, Lu J, Glaspole I, Collard HR, Johannson KA. Exposures and associations with clinical phenotypes in hypersensitivity pneumonitis: a scoping review. *Respir Med* 2021;184:106444.
52. Kern DG, Crausman RS, Durand KT, Nayer A, Kuhn C 3rd. Flock worker's lung: chronic interstitial lung disease in the nylon flocking industry. *Ann Intern Med* 1998;129:261–272.
53. Kern DG, Kuhn C, Ely EW, Pransky GS, Mello CJ, Fraire AE, *et al.* Flock worker's lung: broadening the spectrum of clinicopathology, narrowing the spectrum of suspected etiologies. *Chest* 2000;117:251–259.
54. Weiland DA, Lynch DA, Jensen SP, Newell JD, Miller DE, Crausman RS, *et al.* Thin-section CT findings in flock worker's lung, a work-related interstitial lung disease. *Radiology* 2003;227:222–231.
55. Churg A, Muller NL. Update on silicosis. *Surg Pathol Clin* 2024;17: 193–202.
56. Spagnolo P, Ryerson CJ, Guler S, Feary J, Churg A, Fontenot AP, *et al.* Occupational interstitial lung diseases. *J Intern Med* 2023;294:798–815.
57. Bacchus L, Shah RD, Chung JH, Crabtree TP, Heitkamp DE, Iannettoni MD, *et al.*; Expert Panel on Thoracic Imaging. ACR Appropriateness

Criteria® occupational lung diseases. *J Thorac Imaging* 2016;31: W1–W3.
58. Roggli VL, Gibbs AR, Attanoos R, Churg A, Popper H, Cagle P, *et al.* Pathology of asbestosis—an update of the diagnostic criteria: report of the asbestosis committee of the College of American Pathologists and Pulmonary Pathology Society. *Arch Pathol Lab Med* 2010;134:462–480.
59. Heppleston AG. Prevalence and pathogenesis of pneumoconiosis in coal workers. *Environ Health Perspect* 1988;78:159–170.
60. Cohen RA, Rose CS, Go LHT, Zell-Baran LM, Almberg KS, Sarver EA, *et al.* Pathology and mineralogy demonstrate respirable crystalline silica is a major cause of severe pneumoconiosis in US coal miners. *Ann Am Thorac Soc* 2022;19:1469–1478.
61. Almberg KS, Halldin CN, Blackley DJ, Laney AS, Storey E, Rose CS, *et al.* Progressive massive fibrosis resurgence identified in US coal miners filing for black lung benefits, 1970–2016. *Ann Am Thorac Soc* 2018;15:1420–1426.
62. Chiarchiaro J, Tomsic LR, Strock S, Veraldi KL, Nouraie M, Sellares J, *et al.* A case series describing common radiographic and pathologic patterns of hard metal pneumoconiosis. *Respir Med Case Rep* 2018; 25:124–128.
63. Moriyama H, Kobayashi M, Takada T, Shimizu T, Terada M, Narita J-I, *et al.* Two-dimensional analysis of elements and mononuclear cells in hard metal lung disease. *Am J Respir Crit Care Med* 2007;176: 70–77.
64. Fortarezza F, Perilli M, Della Barbera M, Pezzuto F, Faccioli E, Cocconcelli E, *et al.* Giant cell interstitial pneumonia: case series with comprehensive ultrastructural analyses of "not only" hard metal pneumoconiosis. *Histopathology* 2025;86:450–459.
65. Johkoh T, Lee KS, Nishino M, Travis WD, Ryu JH, Lee HY, *et al.* Chest CT diagnosis and clinical management of drug-related pneumonitis in patients receiving molecular targeting agents and immune checkpoint inhibitors: a position paper from the Fleischner Society. *Chest* 2021; 159:1107–1125.
66. Johkoh T, Lee KS, Nishino M, Travis WD, Ryu JH, Lee HY, *et al.* Chest CT diagnosis and clinical management of drug-related pneumonitis in patients receiving molecular targeting agents and immune checkpoint inhibitors: a position paper from the Fleischner Society. *Radiology* 2021;298:550–566.
67. Hanania AN, Mainwaring W, Ghebre YT, Hanania NA, Ludwig M. Radiation-induced lung injury: assessment and management. *Chest* 2019;156:150–162.
68. Vassallo R, Harari S, Tazi A. Current understanding and management of pulmonary Langerhans cell histiocytosis. *Thorax* 2017;72:937–945.
69. Favara BE, Feller AC, Pauli M, Jaffe ES, Weiss LM, Arico M, *et al.* Contemporary classification of histiocytic disorders. *Med Pediatr Oncol* 1997;29:157–166.
70. Roden AC, Yi ES. Pulmonary Langerhans cell histiocytosis: an update from the pathologists' perspective. *Arch Pathol Lab Med* 2016;140: 230–240.
71. Goyal G, Tazi A, Go RS, Rech KL, Picarsic JL, Vassallo R, *et al.* International expert consensus recommendations for the diagnosis and treatment of Langerhans cell histiocytosis in adults. *Blood* 2022;139: 2601–2621.
72. McCarthy C, Gupta N, Johnson SR, Yu JJ, McCormack FX. Lymphangioleiomyomatosis: pathogenesis, clinical features, diagnosis, and management. *Lancet Respir Med* 2021;9:1313–1327.
73. Gupta N, Finlay GA, Kotloff RM, Strange C, Wilson KC, Young LR, *et al.*; ATS Assembly on Clinical Problems. Lymphangioleiomyomatosis diagnosis and management: high-resolution chest computed tomography, transbronchial lung biopsy, and pleural disease management. An official American Thoracic Society/Japanese Respiratory Society clinical practice guideline. *Am J Respir Crit Care Med* 2017;196:1337–1348.
74. McCormack FX, Gupta N, Finlay GR, Young LR, Taveira-DaSilva AM, Glasgow CG, *et al.*; ATS/JRS Committee on Lymphangioleiomyomatosis. Official American Thoracic Society/Japanese Respiratory Society clinical practice guidelines: lymphangioleiomyomatosis diagnosis and management. *Am J Respir Crit Care Med* 2016;194:748–761.
75. Johnson SR, Cordier JF, Lazor R, Cottin V, Costabel U, Harari S, *et al.*; Review Panel of the ERS LAM Task Force. European Respiratory Society guidelines for the diagnosis and management of lymphangioleiomyomatosis. *Eur Respir J* 2010;35:14–26.
76. Buxbaum JN, Dispenzieri A, Eisenberg DS, Fändrich M, Merlini G, Saraiva MJM, *et al.* Amyloid nomenclature 2022: update, novel proteins, and recommendations by the International Society of Amyloidosis (ISA) Nomenclature Committee. *Amyloid* 2022;29: 213–219.
77. Abe R, Katoh N, Takahashi Y, Takasone K, Yoshinaga T, Yazaki M, *et al.* Distribution of amyloidosis subtypes based on tissue biopsy site—consecutive analysis of 729 patients at a single amyloidosis center in Japan. *Pathol Int* 2021;71:70–79.
78. Khoor A, Colby TV. Amyloidosis of the lung. *Arch Pathol Lab Med* 2017; 141:247–254.
79. Baqir M, Moua T, White D, Yi ES, Ryu JH. Pulmonary nodular and cystic light chain deposition disease: a retrospective review of 10 cases. *Respir Med* 2020;164:105896.
80. Lee JS, Tuder R, Lynch DA. Lymphomatoid granulomatosis: radiologic features and pathologic correlations. *AJR Am J Roentgenol* 2000;175: 1335–1339.
81. Borie R, Wislez M, Antoine M, Cadranel J. Lymphoproliferative disorders of the lung. *Respiration* 2017;94:157–175.
82. Liu AY, Nabel CS, Finkelman BS, Ruth JR, Kurzrock R, van Rhee F, *et al.* Idiopathic multicentric Castleman's disease: a systematic literature review. *Lancet Haematol* 2016;3:e163–e175.
83. Murakami M, Johkoh T, Hayashi S, Ohshima S, Mizuki M, Nakatsuka S-I, *et al.* Clinicopathologic characteristics of 342 patients with multicentric Castleman disease in Japan. *Mod Rheumatol* 2020;30:843–851.
84. Kligerman SJ, Auerbach A, Franks TJ, Galvin JR. Castleman disease of the thorax: clinical, radiologic, and pathologic correlation: from the Radiologic Pathology Archives. *Radiographics* 2016;36:1309–1332.
85. Nickerson ML, Warren MB, Toro JR, Matrosova V, Glenn G, Turner ML, *et al.* Mutations in a novel gene lead to kidney tumors, lung wall defects, and benign tumors of the hair follicle in patients with the Birt-Hogg-Dube syndrome. *Cancer Cell* 2002;2:157–164.
86. Daccord C, Good JM, Morren MA, Bonny O, Hohl D, Lazor R. Birt-Hogg-Dube syndrome. *Eur Respir Rev* 2020;29:200042.
87. Birt AR, Hogg GR, Dube WJ. Hereditary multiple fibrofolliculomas with trichodiscomas and acrochordons. *Arch Dermatol* 1977;113: 1674–1677.
88. Alves Júnior SF, Zanetti G, Alves de Melo AS, Souza AS, Souza LS, de Souza Portes Meirelles G, *et al.* Neurofibromatosis type 1: state-of-the-art review with emphasis on pulmonary involvement. *Respir Med* 2019; 149:9–15.
89. Wang MX, Dillman JR, Guccione J, Habiba A, Maher M, Kamel S, *et al.* Neurofibromatosis from head to toe: what the radiologist needs to know. *Radiographics* 2022;42:1123–1144.
90. Geberhiwot T, Wasserstein M, Wanninayake S, Bolton SC, Dardis A, Lehman A, *et al.* Consensus clinical management guidelines for acid sphingomyelinase deficiency (Niemann-Pick disease types A, B and A/B). *Orphanet J Rare Dis* 2023;18:85.
91. Borie R, Crestani B, Guyard A, Lidove O. Interstitial lung disease in lysosomal storage disorders. *Eur Respir Rev* 2021;30:200363.
92. Svensson CK, Feldt-Rasmussen U, Backer V. Fabry disease, respiratory symptoms, and airway limitation—a systematic review. *Eur Clin Respir J* 2015;2:26721.
93. Ahmed H, Backer V, Effraimidis G, Rasmussen AK, Kistorp CM, Feldt-Rasmussen U. Respiratory impairments in patients suffering from Fabry disease—a cross-sectional study. *Chron Respir Dis* 2024;21: 14799731231221821.
94. Brown LK, Miller A, Bhuptani A, Sloane MF, Zimmerman MI, Schilero G, *et al.* Pulmonary involvement in Fabry disease. *Am J Respir Crit Care Med* 1997;155:1004–1010.
95. Sun JD, Shum T, Behzadi F, Hammer MM. Imaging findings of thoracic lymphatic abnormalities. *Radiographics* 2022;42:1265–1282.
96. Kadakia KC, Patel SM, Yi ES, Limper AH. Diffuse pulmonary lymphangiomatosis. *Can Respir J* 2013;20:52–54.
97. Swensen SJ, Hartman TE, Mayo JR, Colby TV, Tazelaar HD, Muller NL. Diffuse pulmonary lymphangiomatosis: CT findings. *J Comput Assist Tomogr* 1995;19:348–352.
98. Tazelaar HD, Kerr D, Yousem SA, Saldana MJ, Langston C, Colby TV. Diffuse pulmonary lymphangiomatosis. *Hum Pathol* 1993;24: 1313–1322.
99. Crouser ED, Maier LA, Wilson KC, Bonham CA, Morgenthau AS, Patterson KC, *et al.* Diagnosis and detection of sarcoidosis. An official

American Thoracic Society clinical practice guideline. *Am J Respir Crit Care Med* 2020;201:e26–e51.
100. Desai SR, Sivarasan N, Johannson KA, George PM, Culver DA, Devaraj A, *et al.*; Sarcoid Delphi Group. High-resolution CT phenotypes in pulmonary sarcoidosis: a multinational Delphi consensus study. *Lancet Respir Med* 2024;12:409–418.
101. Castellana G, Castellana G, Gentile M, Castellana R, Resta O. Pulmonary alveolar microlithiasis: review of the 1022 cases reported worldwide. *Eur Respir Rev* 2015;24:607–620.
102. Sumikawa H, Johkoh T, Tomiyama N, Hamada S, Koyama M, Tsubamoto M, *et al.* Pulmonary alveolar microlithiasis: CT and pathologic findings in 10 patients. *Monaldi Arch Chest Dis* 2005;63:59–64.
103. Kosciuk P, Meyer C, Wikenheiser-Brokamp KA, McCormack FX. Pulmonary alveolar microlithiasis. *Eur Respir Rev* 2020;29:200024.
104. Shaw BM, Shaw SD, McCormack FX. Pulmonary alveolar microlithiasis. *Semin Respir Crit Care Med* 2020;41:280–287.
105. Walkoff L, Dixit AS, Ryu JH, Chung JH, Cox CW. Diffuse pulmonary ossification on high-resolution computed tomography in idiopathic pulmonary fibrosis, systemic sclerosis-related interstitial lung disease, and chronic hypersensitivity pneumonitis: a comparative study. *J Comput Assist Tomogr* 2020;44:667–672.
106. Egashira R, Jacob J, Kokosi MA, Brun A-L, Rice A, Nicholson AG, *et al.* Diffuse pulmonary ossification in fibrosing interstitial lung diseases: prevalence and associations. *Radiology* 2017;284:255–263.
107. Nishioka Y, Toyoda Y, Egashira R, Johkoh T, Terasaki Y, Hebisawa A, *et al.* Nationwide retrospective observational study of idiopathic dendriform pulmonary ossification: clinical features with a progressive phenotype. *BMJ Open Respir Res* 2022;9:e001337.
108. Gruden JF, Green DB, Legasto AC, Jensen EA, Panse PM. Dendriform pulmonary ossification in the absence of usual interstitial pneumonia: CT features and possible association with recurrent acid aspiration. *AJR Am J Roentgenol* 2017;209:1209–1215.
109. Ueno M, Egashira R, Hashisako M, Fujimoto K, Fukuda T, Hayashida Y, *et al.* Idiopathic dendriform pulmonary ossification as the phenotype of interstitial lung abnormalities: CT-pathologic correlation and prevalence. *Jpn J Radiol* 2024;42:993–1002.